DISORDERS OF THE CONJUNCTIVA

Dunera R. Ilako

APPLIED ANATOMY

- **Epithelium**
  - Stratified, squamous, non-keratinized
- **Stroma**
  - Highly vascularised
- **Mucin secretors**
  - Goblet cells
  - Crypts of Henle
  - Glands of Manz
- **Accessory lacrimal glands**
  - Kraus and Wolfring
- **Three clinical parts**
  - Palpebral, Forniceal, Bulbar.

CLINICAL EVALUATION

- Clinical Feature for differential diagnosis
  - Symptoms
  - Types of discharge
  - Conjuntival appearance
  - Presence of membranes
  - Lymphadenopathy

SYMPTOMS

- Non-specific
  - Lacrimation
  - Irritation
  - Stinging
  - Burning
  - Photophobia
  - +/- pain & foreign sensation

TYPE OF DISCHARGE

- Watery
- Mucoid
- Purulent
- Mucopurulent

CLINICAL APPEARANCE

- Conjunctival injection
- Sub-conjunctival hemorrhages
- Follicular reaction
- Papillary reaction
- Edema
- Scarring

CONT.

MEMBRANES

- True membranes
- Pseudomebranes

LYMPHADENOPATHY

- Infections: viral, bacterial, chlamydial
- Parinaud's syndrome/ Dorsal Midbrain syndrome/ Vertical Gaze Palsy/ Sunset sign
  - Inability to move the eyes up due to a tumor in the pineal gland which compresses the vertical gaze center.

CONJUNCTIVAL DISORDERS

- **INFLAMMATORY DISEASE:**
  - Bacterial
  - Chlamydial
  - Viral
  - Parasitic
  - Allergic
- **CONJUNCTIVAL DEGENERATION/ BENIGN TUMORS:**
  - Pinguecula
  - Pterygium
  - Limbal dermoid
  - Actinic keratosis
  - Squamous papilloma
- **PREMALIGNANT**:
  - Primary Acquired Melanosis
- **TUMORS**
  - Squamous cell carcinoma
  - Malignant melanoma
  - KS
    Lymphoma
- **VITAMIN A DEFICIENCY**
- **IMMUNOBULLOUS DISEASE**

CONJUNCTIVAL INFECTIONS

- **Bacterial**
  - Simple Bacterial
  - Gonococcal Keratoconjunctivitis
- **Viral**
  - Adenoviral keratoconjunctivitis
  - Molluscum contagiosum conjunctivitis
  - Herpes simplex virus conjunctivitis
- **Chlamydial**
  - Adult
  - Neonatal
  - Trachoma

SIMPLE BACTERIAL CONJUNCTIVITIS

Signs

Crusted eyelids and conjunctival injection

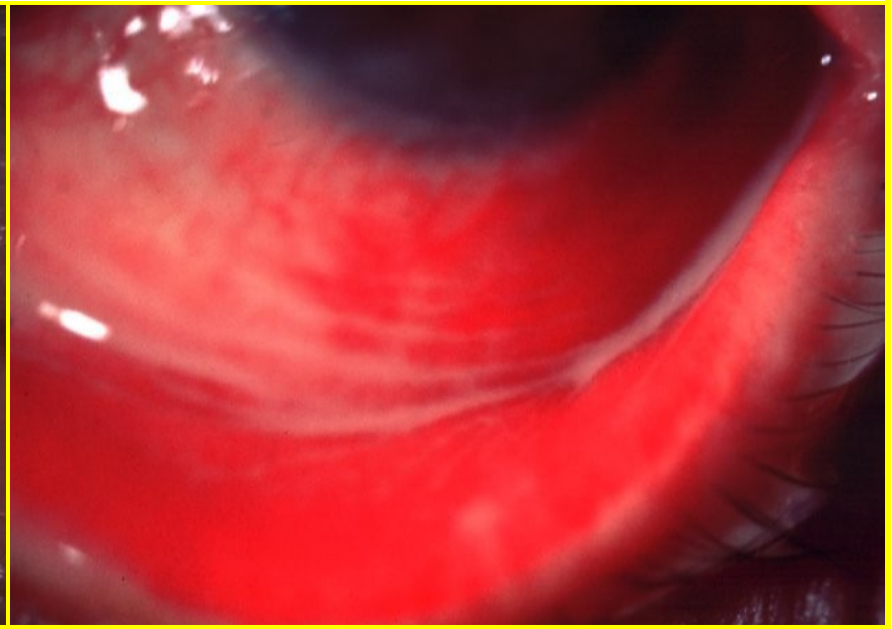

Subacute onset of mucopurulent discharge

Treatment - broad-spectrum topical antibiotics

GONOCOCCAL KERATOCONJUNCTIVITIS

Signs

Acute, profuse, purulent discharge, hyperaemia and chemosis

Complications

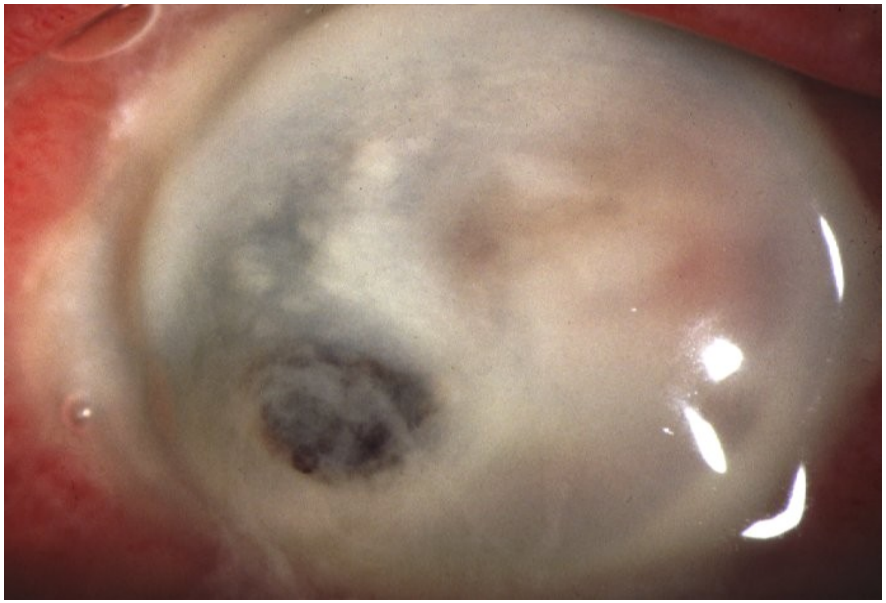

Corneal ulceration, perforation and endophthalmitis if severe

Treatmen

- **Topical gentamicin and bacitracin**
- **Intravenous cefoxitin or cefotaxime**

Adenoviral Keratoconjunctivitis

- Pharyngoconjunctival fever
  - Adenovirus types 3 and 7
  - Typically affects children
  - Upper respiratory tract infection
  - Keratitis in 30% - usually mild

- Epidemic keratoconjunctivitis
  - Adenovirus types 8 and 19
  - Very contageous
  - No systemic symptoms
  - Keratitis in 80% of cases - may be severe

Signs of conjunctivitis

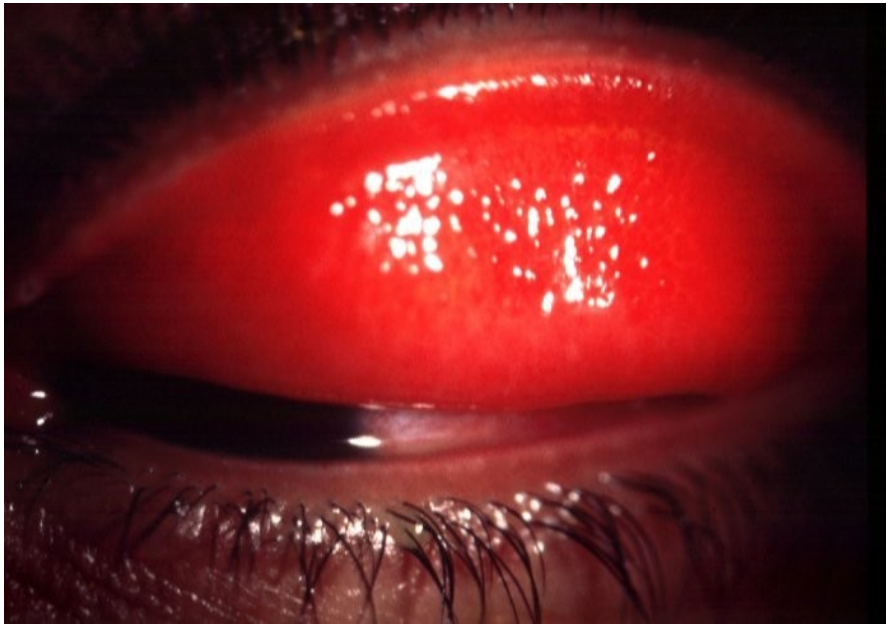

Usually bilateral, acute watery
discharge and follicles

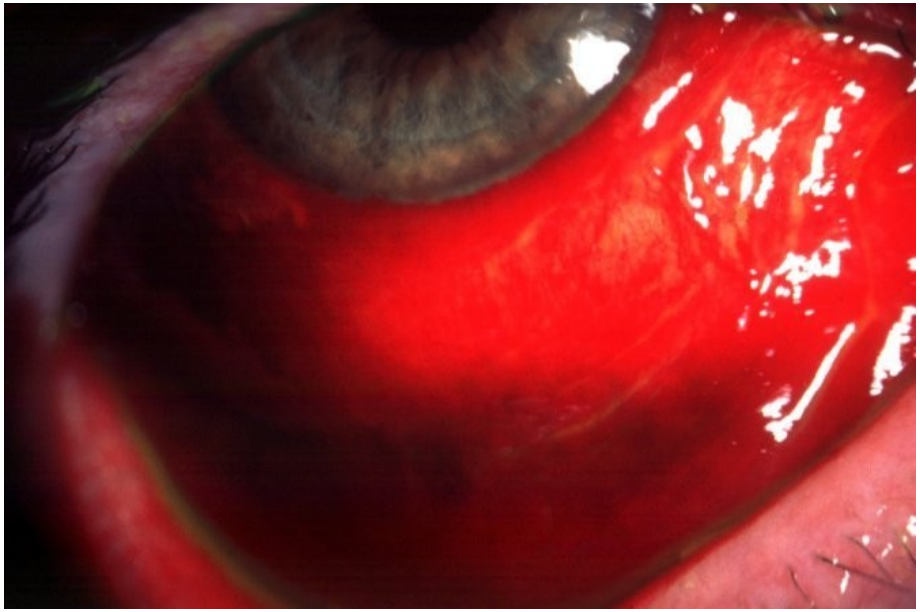

Subconjunctival haemorrhages and
pseudomembranes if severe

Treatment - symptomatic

Signs of Keratitis



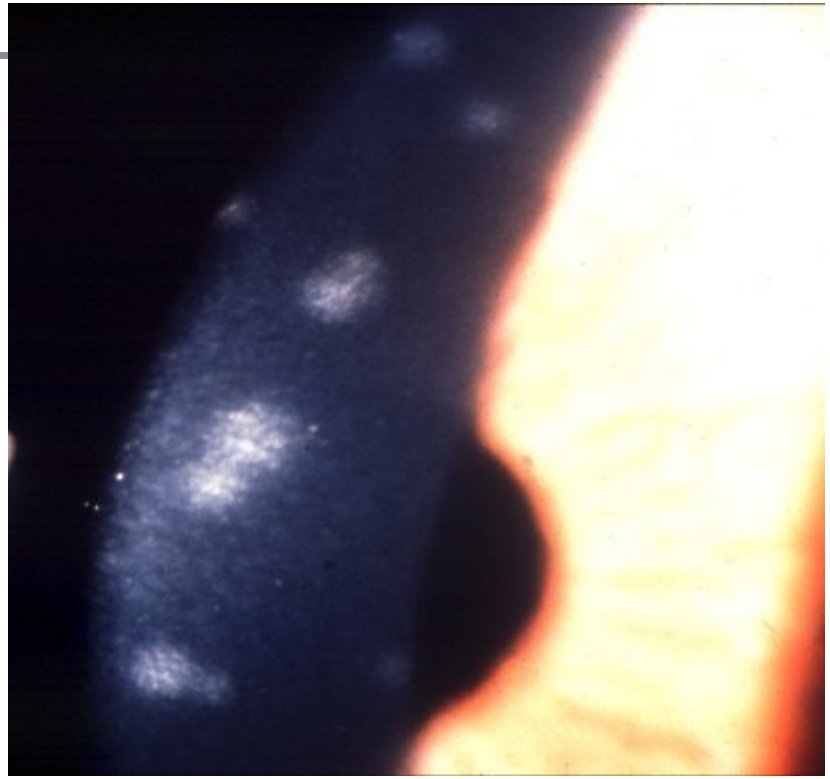

Focal, epithelial keratitis

Transient

Focal, subepithelial keratitis

May persist for months

Treatment

topical steroids if visual acuity diminished by subepithelial keratitis

Molluscum Contagiosum Conjunctivitis

Signs

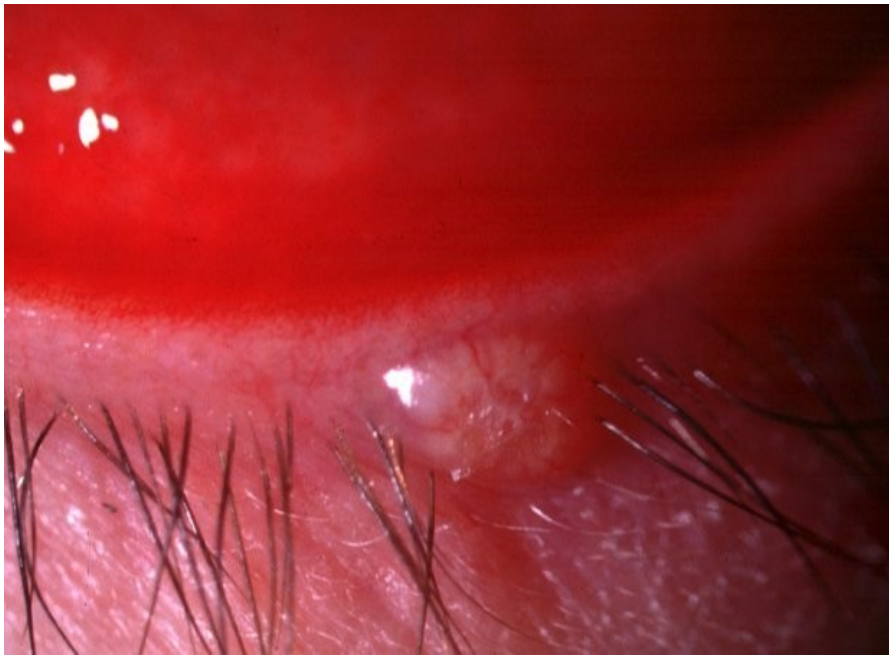

Waxy, umbilicated eyelid nodule

May be multiple

Ispilateral, chronic, mucoid discharge

Follicular conjuntivitis

Treatment **destruction of eyelid lesion**

Herpes simplex conjunctivitis

Signs

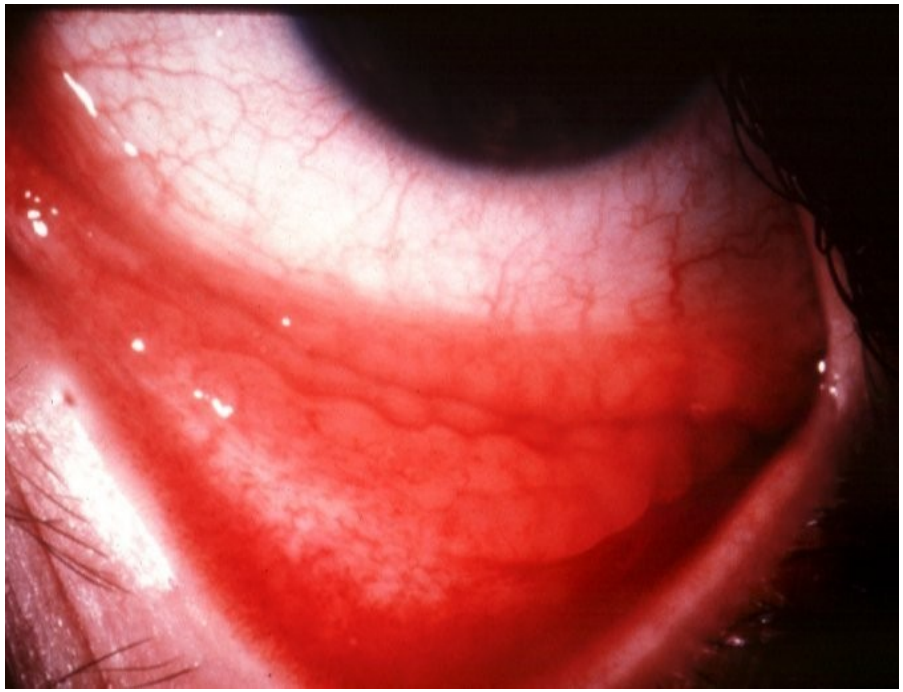

Unilateral eyelid vesicles

Acute follicular conjunctivitis

Treatment **topical antivirals to prevent keratitis**

Rhinosporidiosis

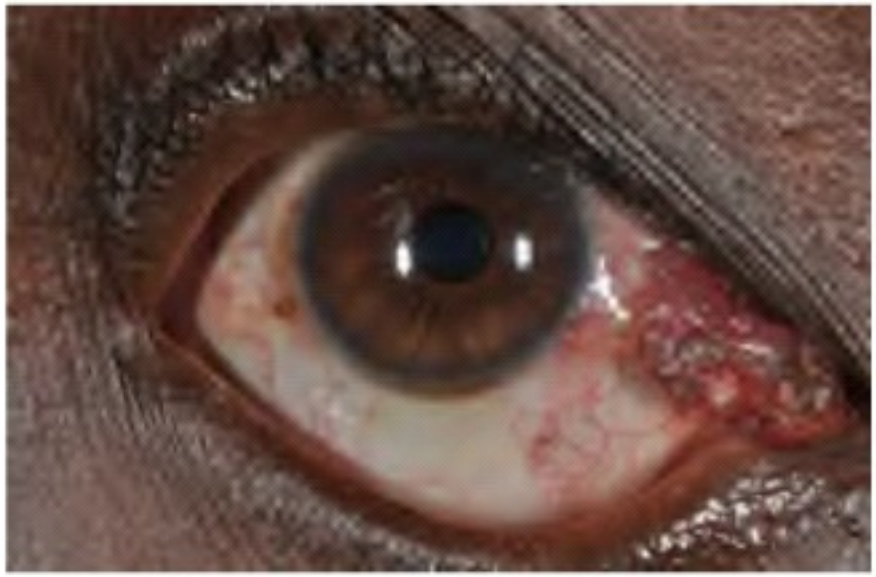

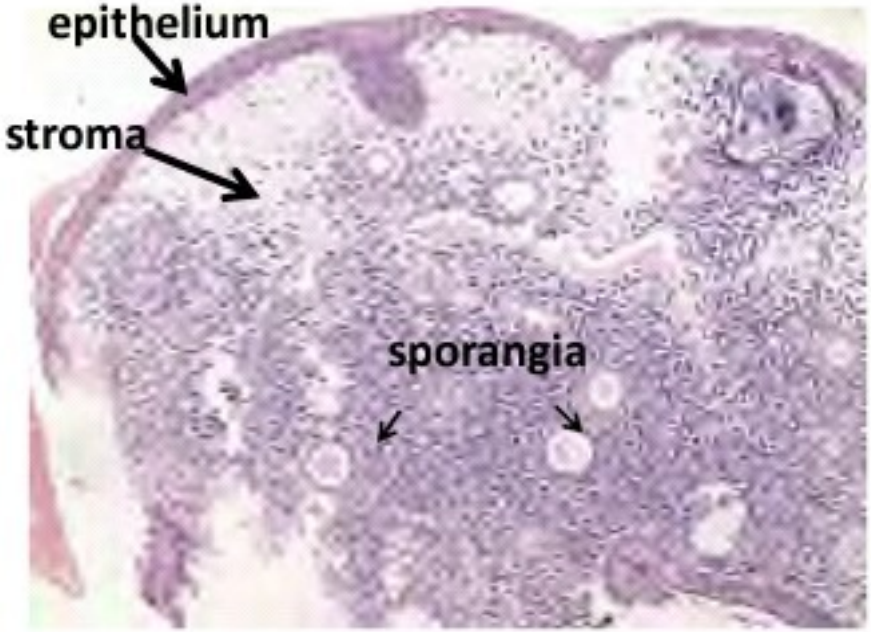

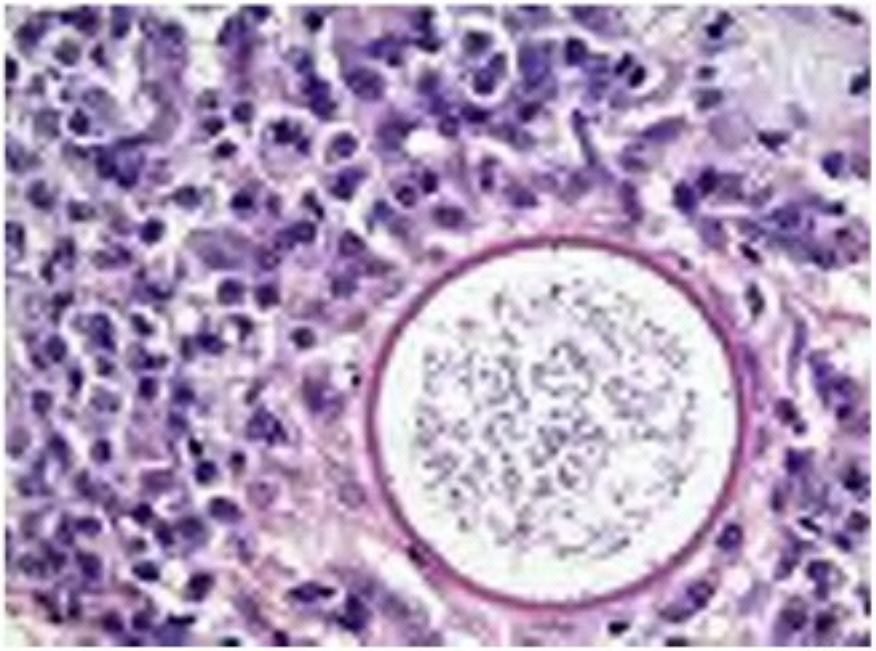

- Parasitic infection
- *Rhinosporidium seeberi*
- Usually acquired from nasal mucosa trauma then spreads by autoinoculation

Neonatal chlamydial conjunctivitis

- **Presents between 5 and 19 days after birth**
- **May be associated with otitis, rhinitis and pneumonitis**

Mucopurulent papillary conjunctivitis

Treatment - topical tetracycline and oral erythromycin

ALLERGIC CONJUNCTIVITIS

1. **Allergic rhinoconjunctivitis**

2. **Vernal keratoconjunctivitis**

3. **Atopic keratoconjunctivitis**

Allergic rhinoconjunctivitis

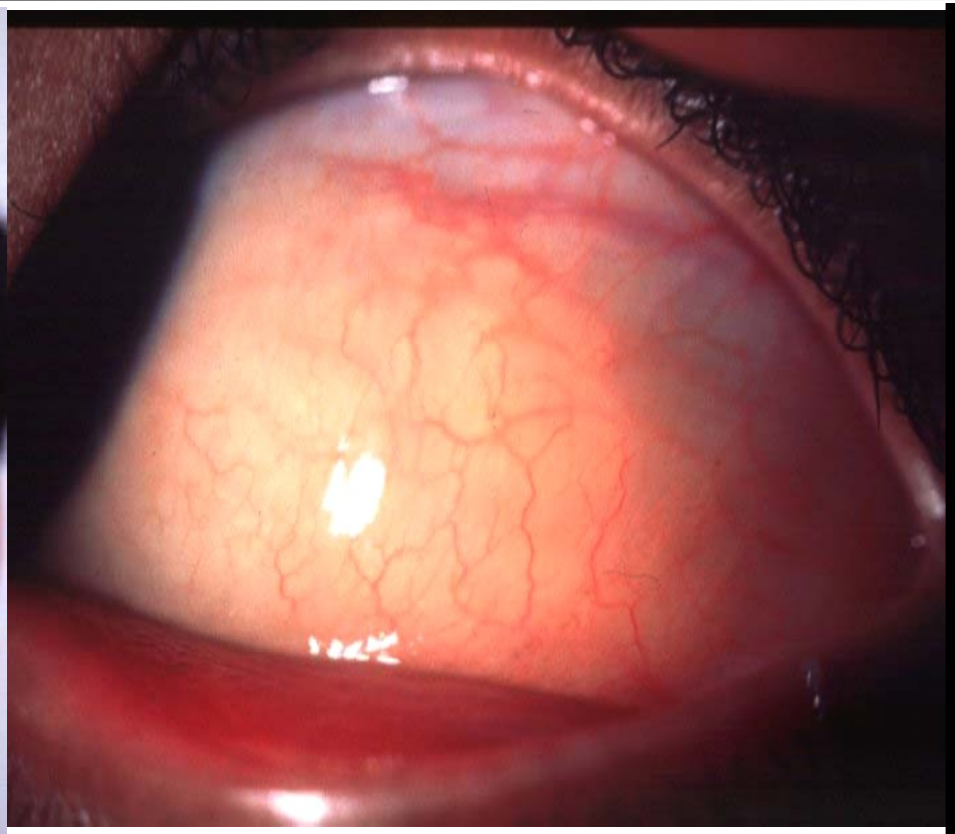

Transient conjunctival oedema

Vernal Keratoconjunctivitis

Frequently associated with atopy: asthma, hay fever and dermatitis

- Recurrent, bilateral
- Affects children and young adults
- More common in males and in warm climates
- Itching, mucoid discharge and lacrimation

Types

- Palpebral
- Limbal
- Mixed

Treatment

- Topical mast cell stabilizers
- Topical steroids

Progression of vernal conjunctivitis

Diffuse papillary hypertrophy, most marked on superior tarsus

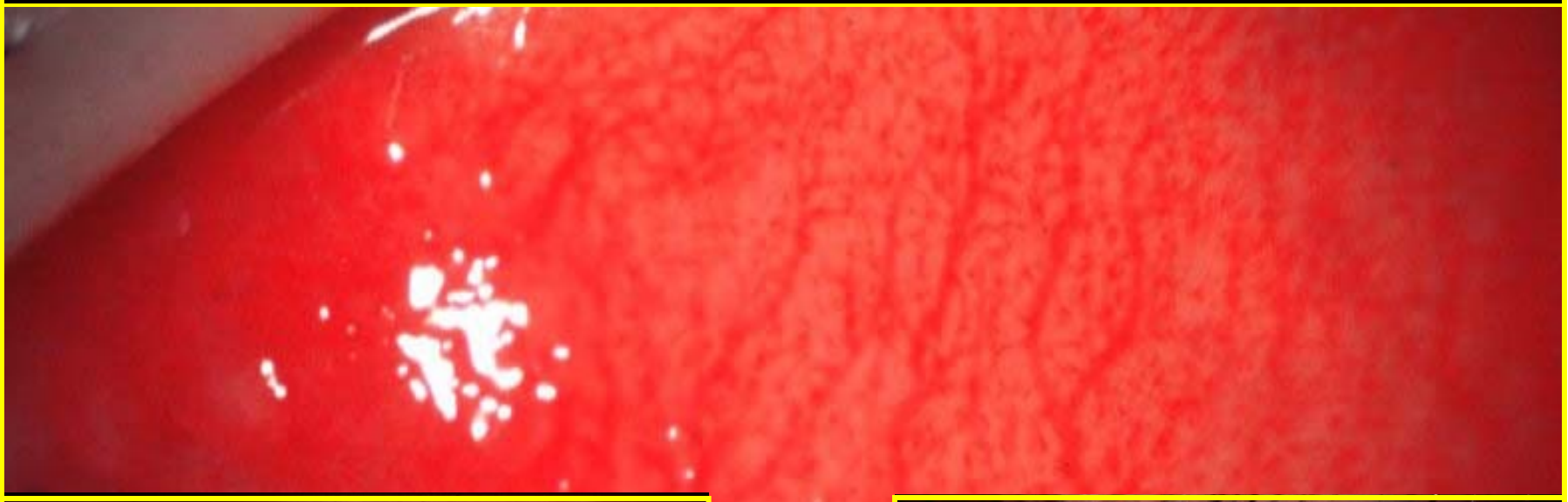

Formation of cobblestone papillae

Rupture of septae → giant papilla

Limbal vernal

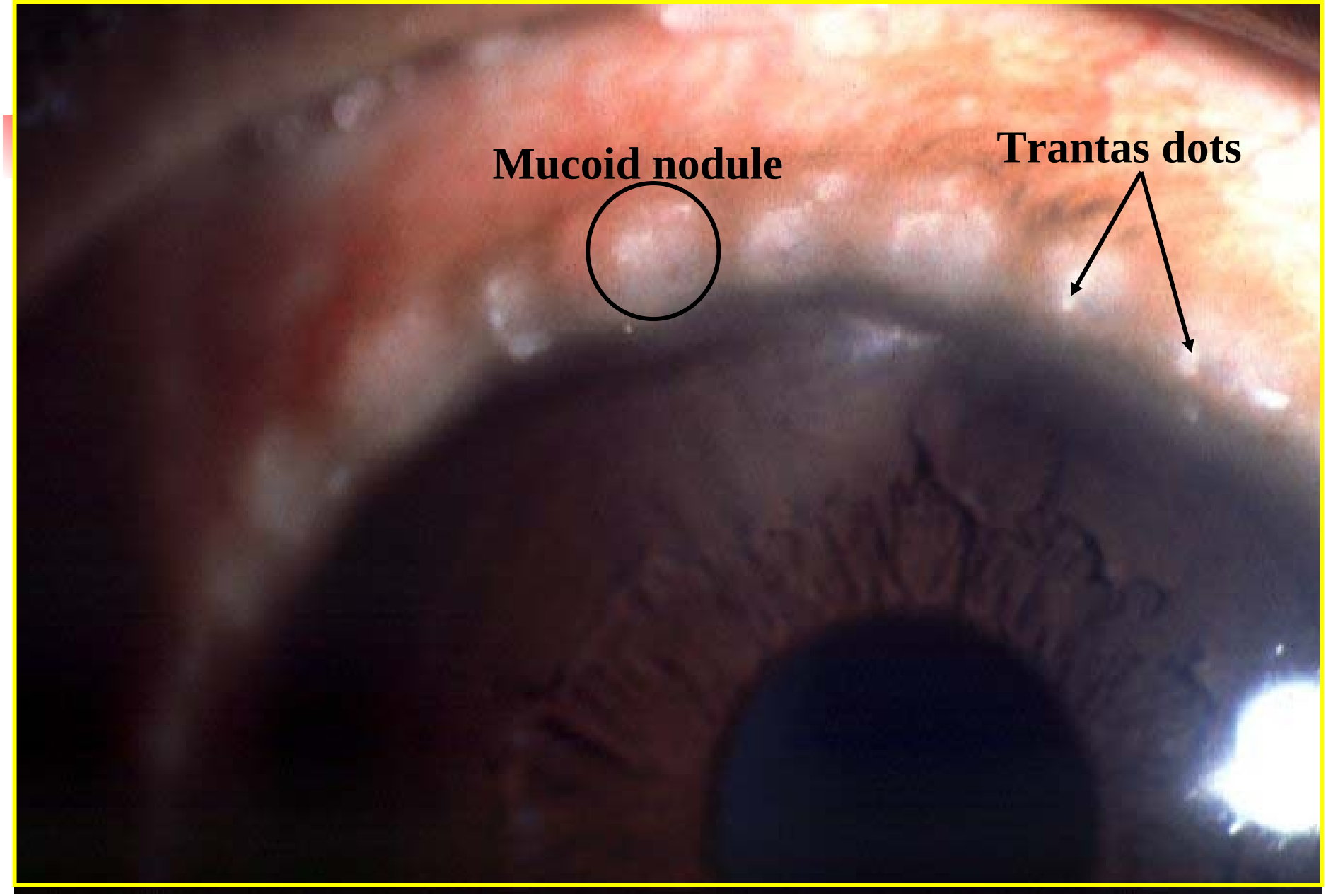

Progression of Vernal Keratopathy

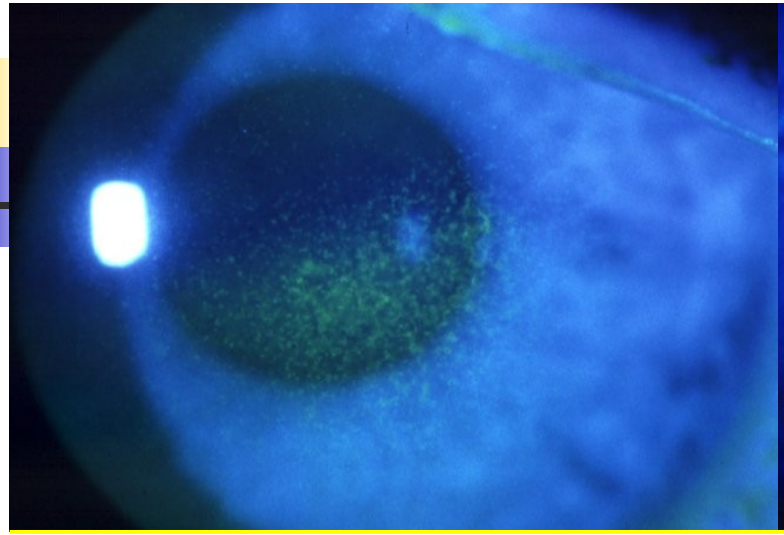

Punctate epitheliopathy

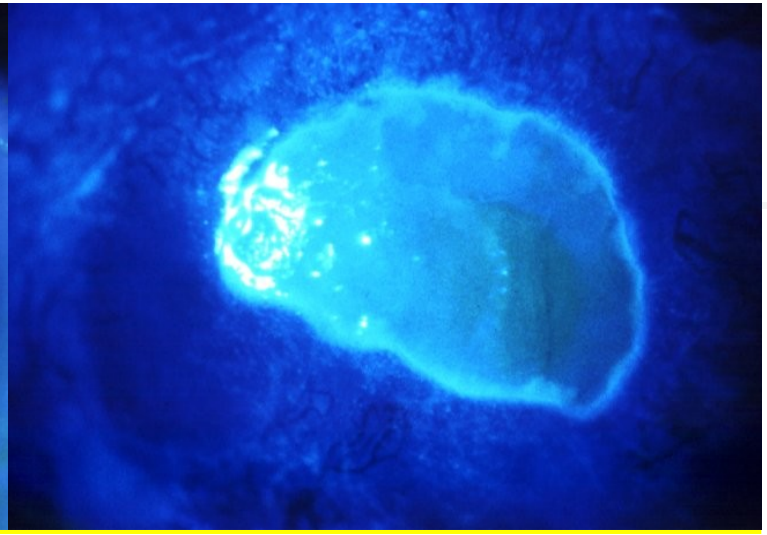

Epithelial macroerosions

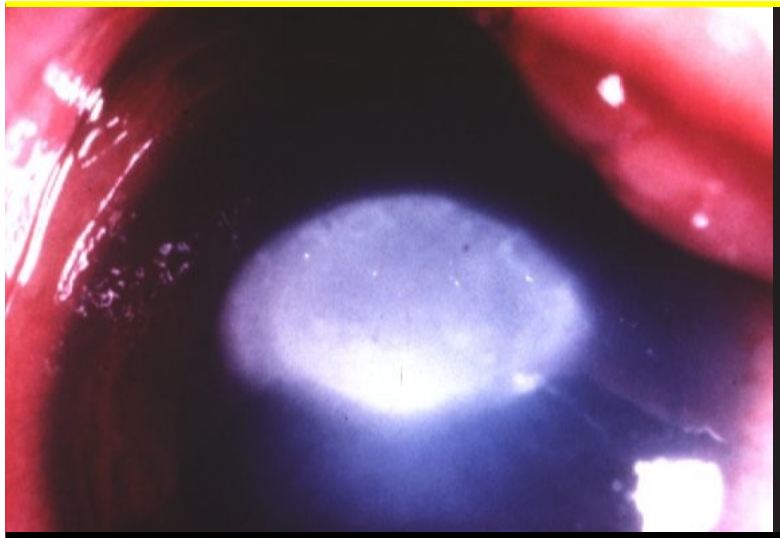

Plaque formation (shield ulcer)

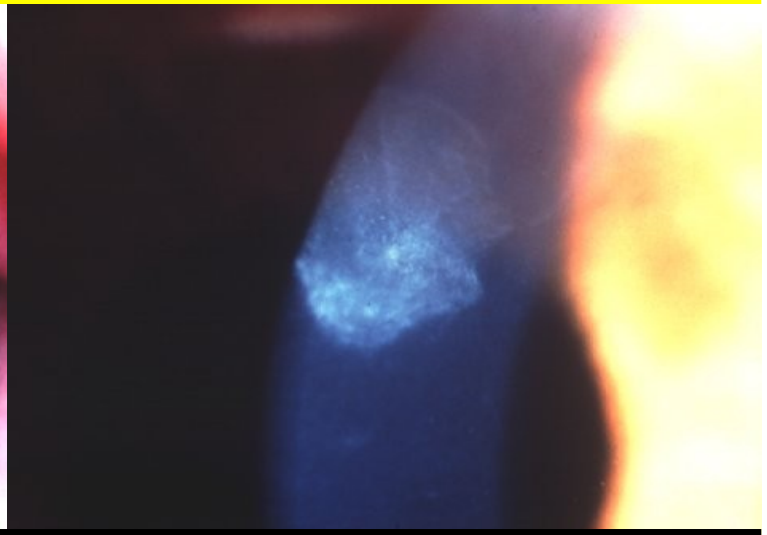

Subepithelial scarring

Atopic Keratoconjunctivitis

Typically affects young patients with atopic dermatitis

Eyelids are red, thickened, macerated and fissured

Progression of atopic conjunctivitis

Infiltration of tarsal conjunctiva causing featureless appearance

Inferior forniceal papillae

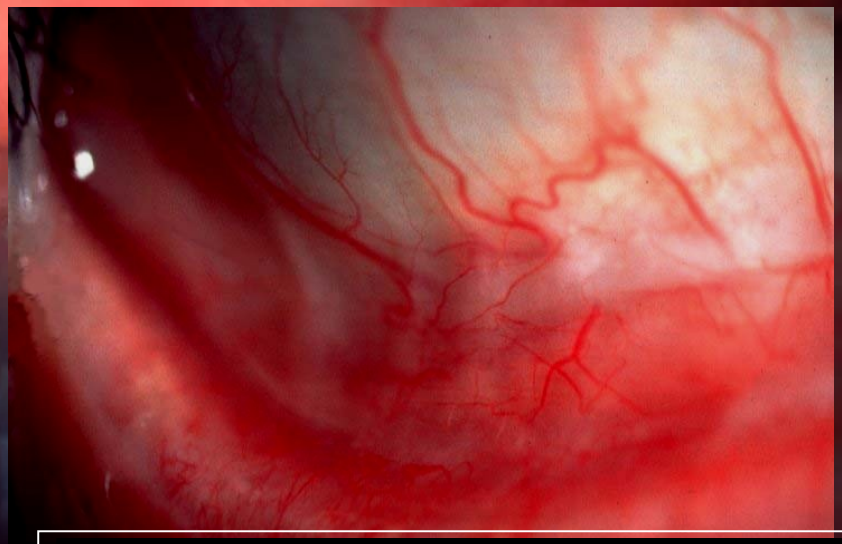

Mild symblepharon formation

Progression of Atopic Keratopathy

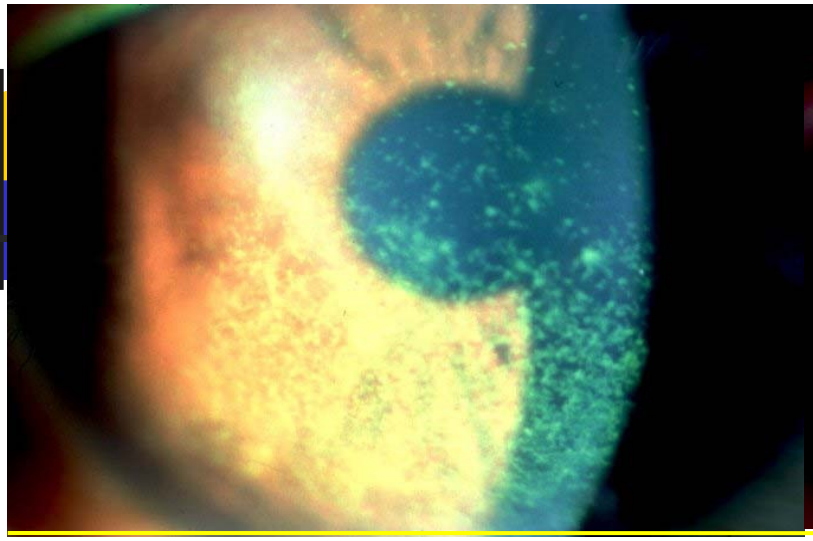

Punctate epitheliopathy

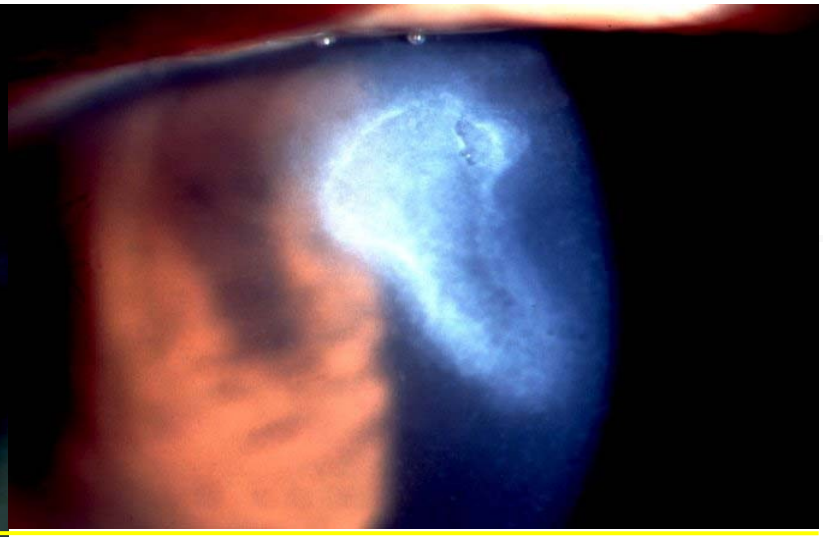

Persistent epithelial defects

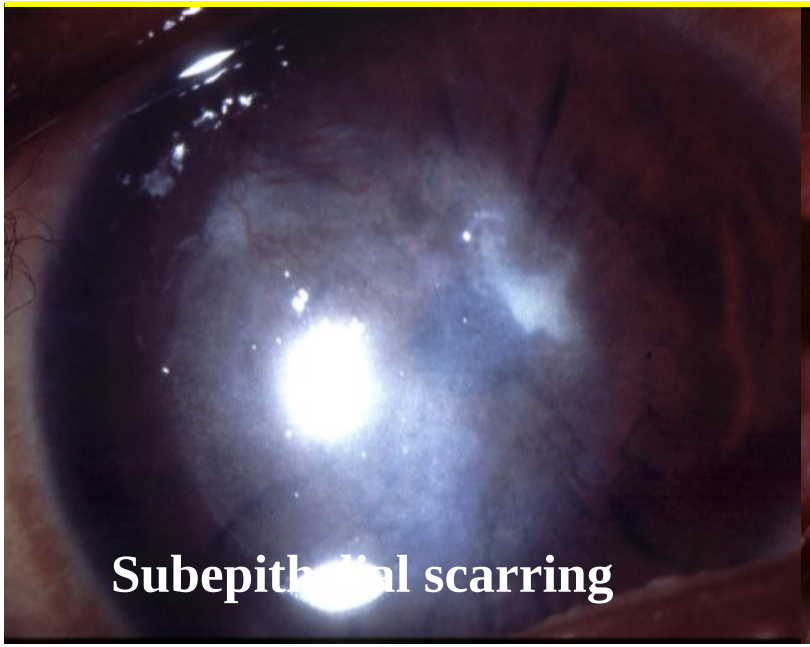

Subepithelial scarring

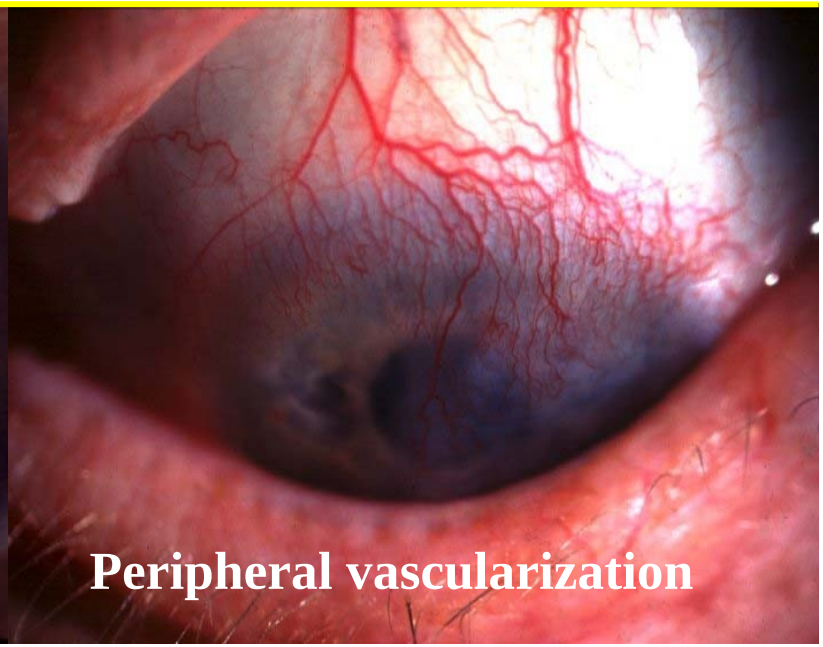

Peripheral vascularization

Conjunctival Tumours

- Benign
  - Naevus
  - Papilloma
  - Epibulbar dermoid
  - Lipodermoid
- Pre-malignant
  - Primary acquired melanosis (PAM)
  - Intraepithelial neoplasia (carcinoma *in situ)*
- Malignant
  - Melanoma
  - Squamous cell carcinoma
  - Kaposi sarcoma
  - Lymphoma

Naevus

- Presents in first two decades
- Sharply demarcated and slightly elevated

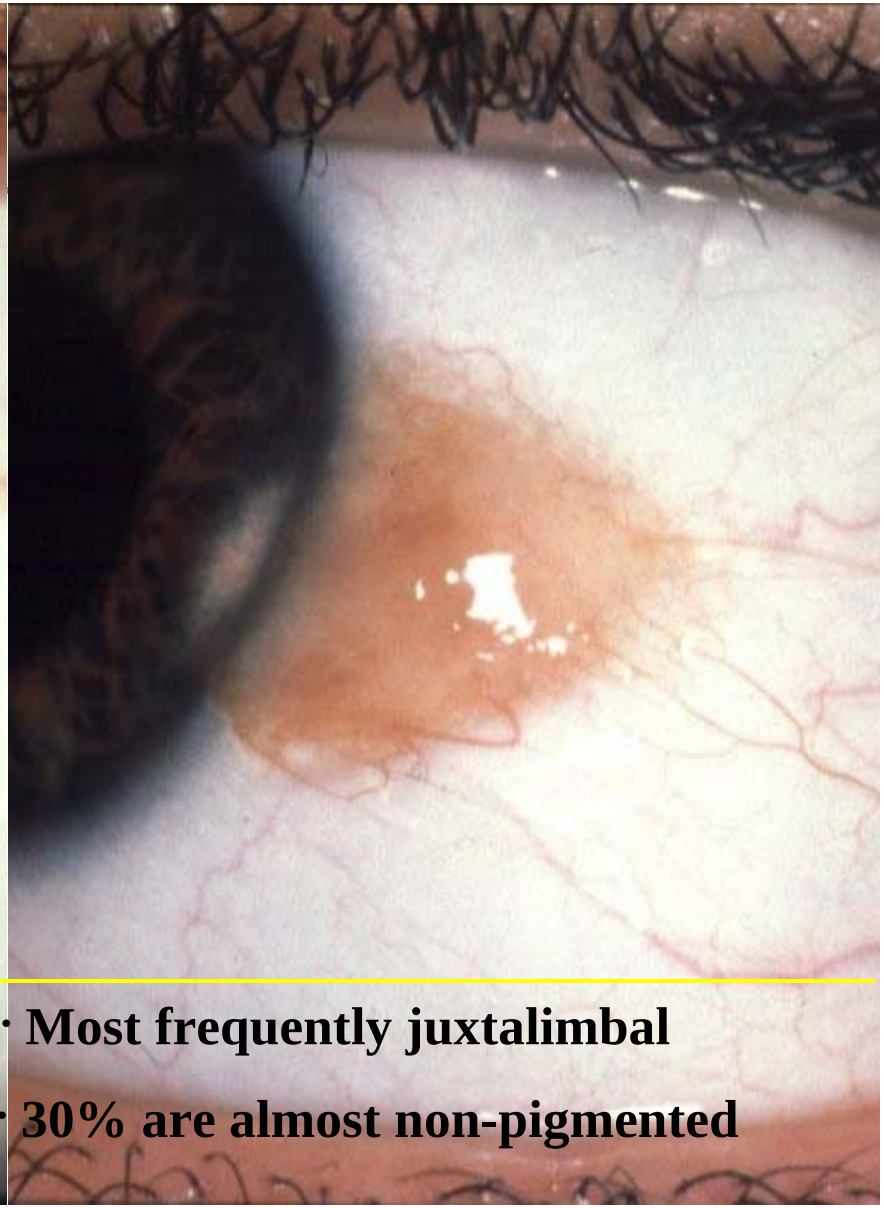

- Most frequently juxtalimbal
- 30% are almost non-pigmented

Papilloma

Pedunculated

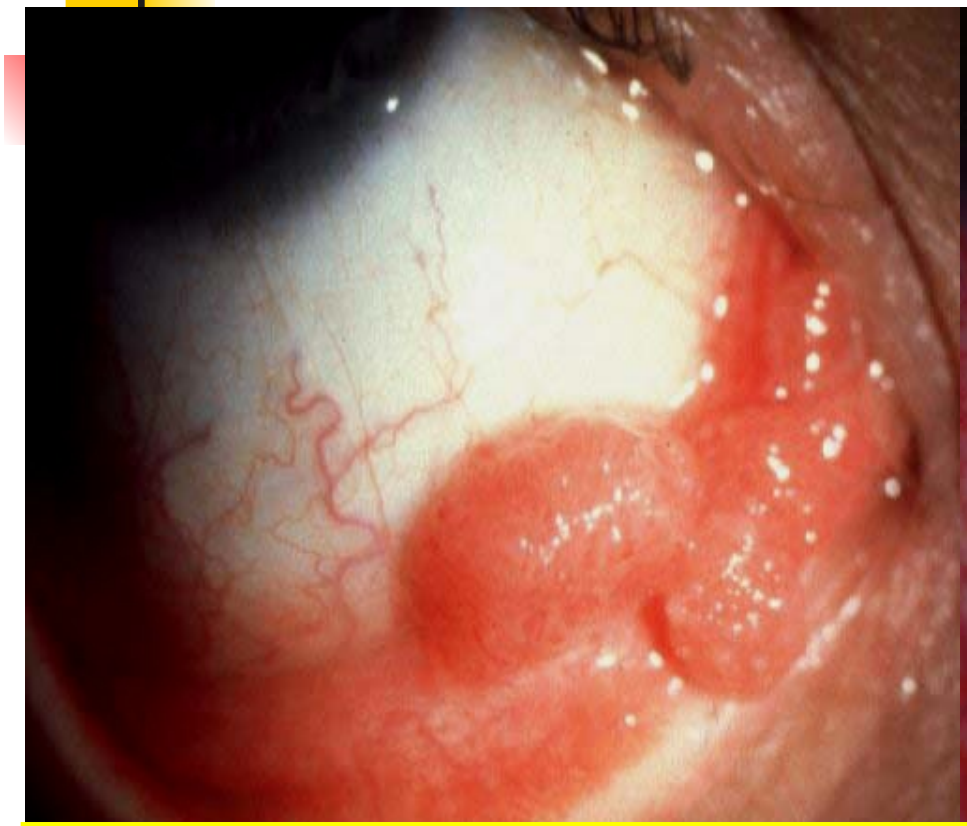

- Presents in childhood or early adulthood
- Infection with papilloma virus
- May be multiple and bilateral

Sessile

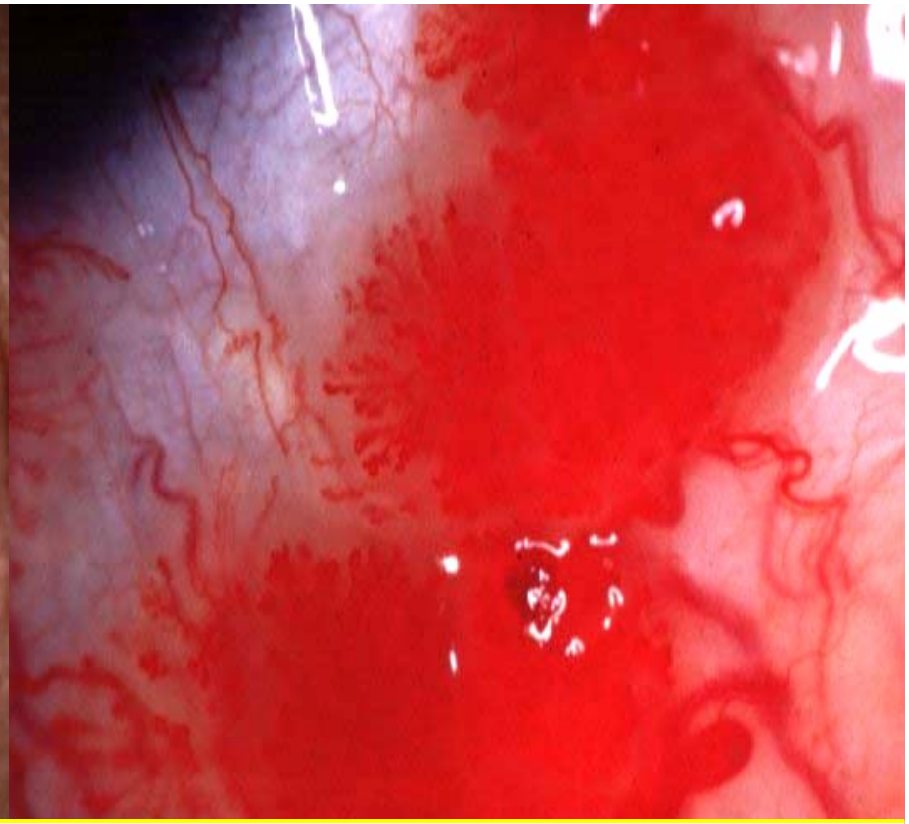

- Presents in middle age
- Not caused by infection
- Single and unilateral

Epibulbar dermoid

Signs

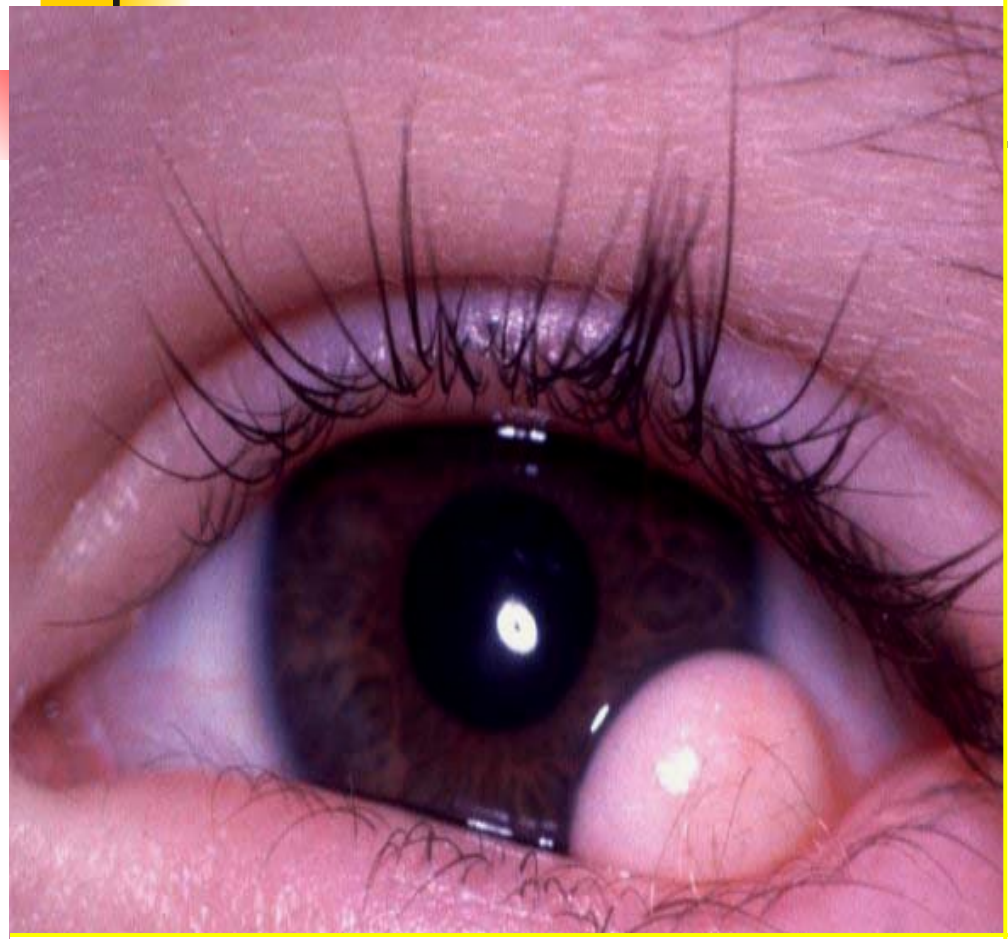

- Presents in childhood
- Smooth, soft mass
- Usually juxtalimbal

Association

- Occasionally Goldenhar syndrome

Lipodermoid

- Presents in adulthood
- Soft, movable, subconjunctival mass
- Most frequently at outer canthus

Intraepithelial neoplasia
(carcinoma *in situ*)

Signs	Progression
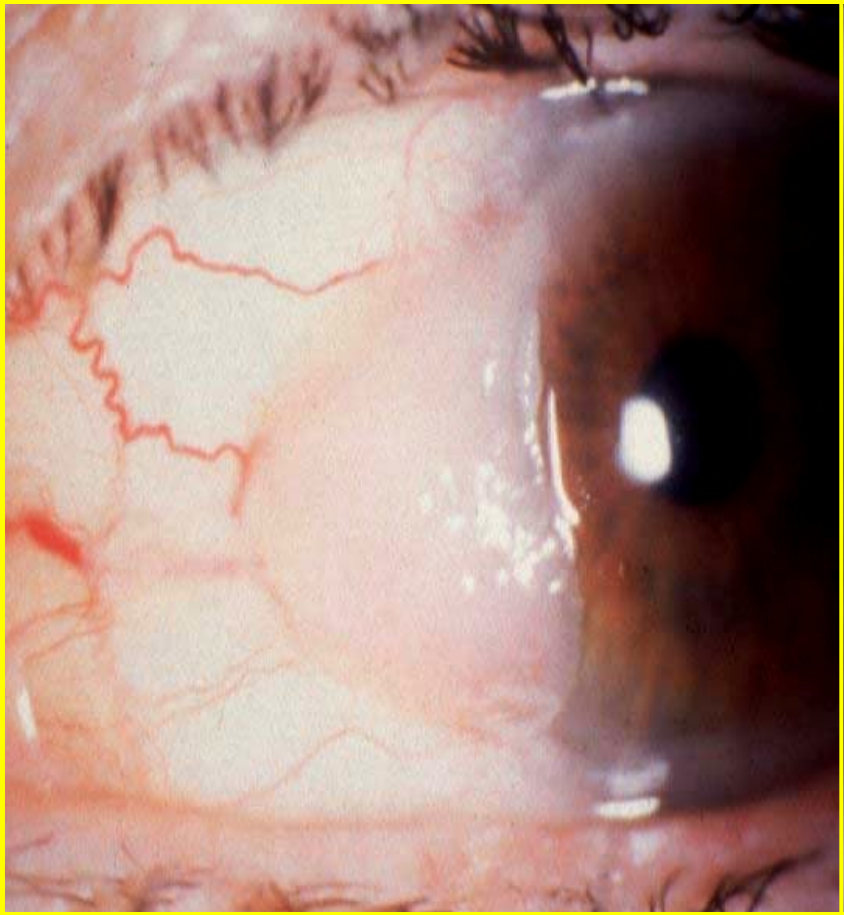	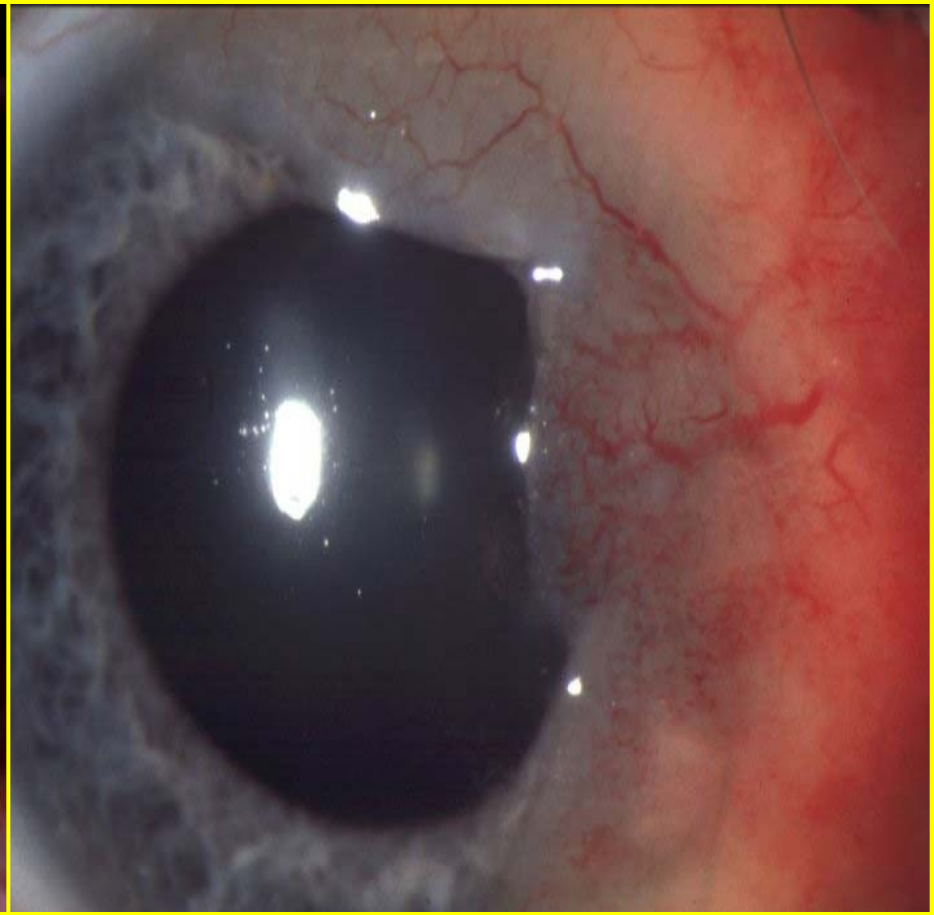
• Presents in late adulthood • Juxtalimbal fleshy avascular mass	• May become vascular and extend onto cornea • Malignant transformation is uncommon

Primary acquired melanosis (PAM)

Signs	Types
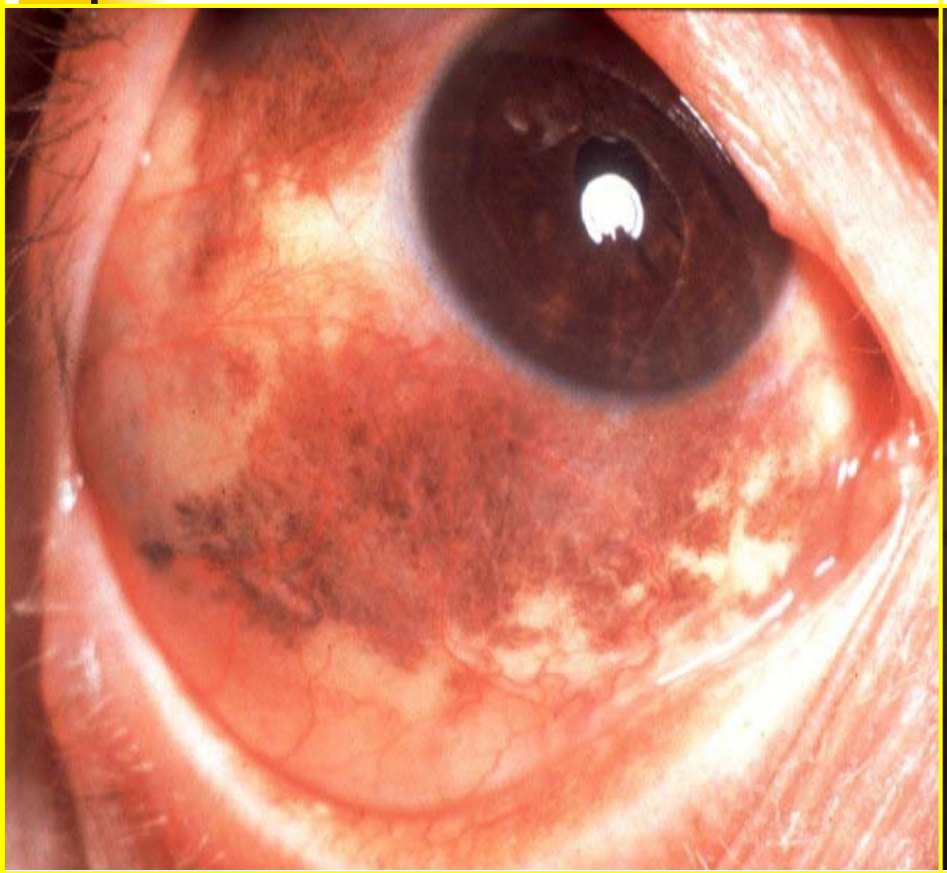	
• Presents in late adulthood • Unilateral, irregular areas of flat, brown pigmentation • May involve any part of conjunctiva	• PAM without atypia is benign • PAM with atypia is pre-malignant

Conjunctival melanoma

From PAM with atypia	From naevus	Primary
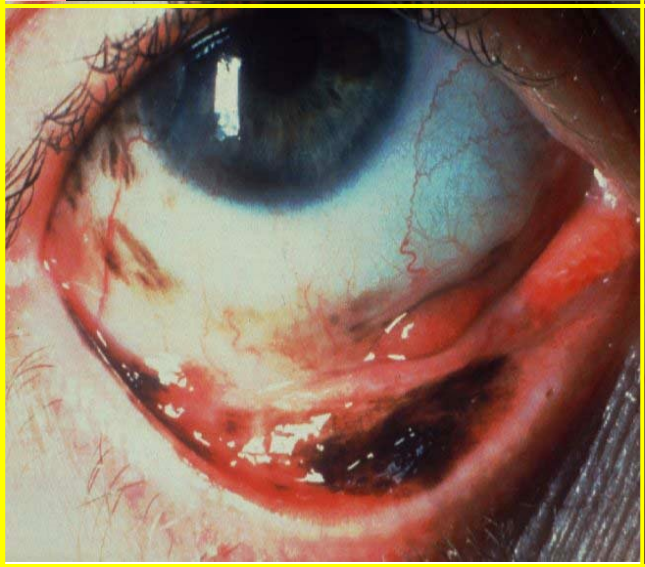	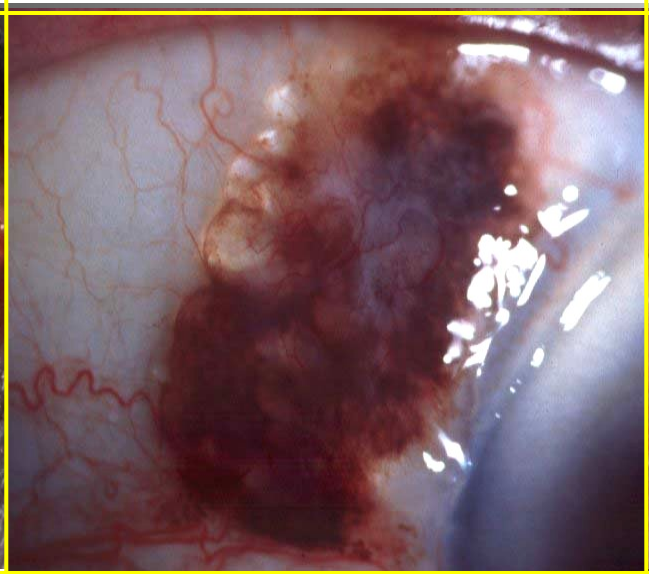	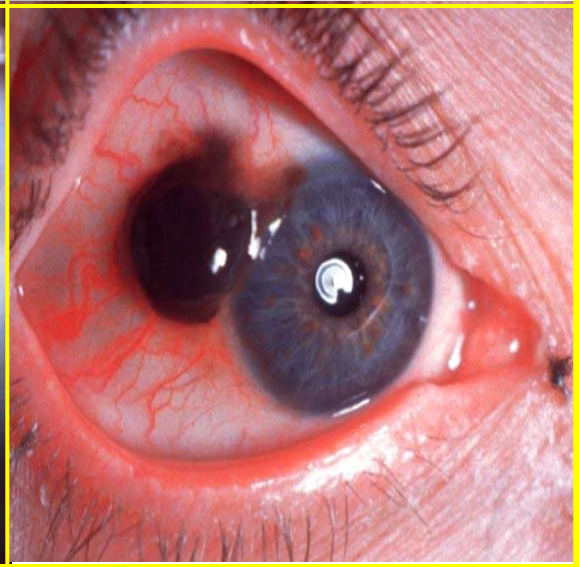
• Most common type • Sudden appearance of nodules in PAM	• Very rare • Sudden increase in size or pigmentation	• Solitary nodule • Frequently juxtalimbal but may be anywhere

Treatment of conjunctival melanoma

Localized tumour	Diffuse tumour	Orbital recurrence
		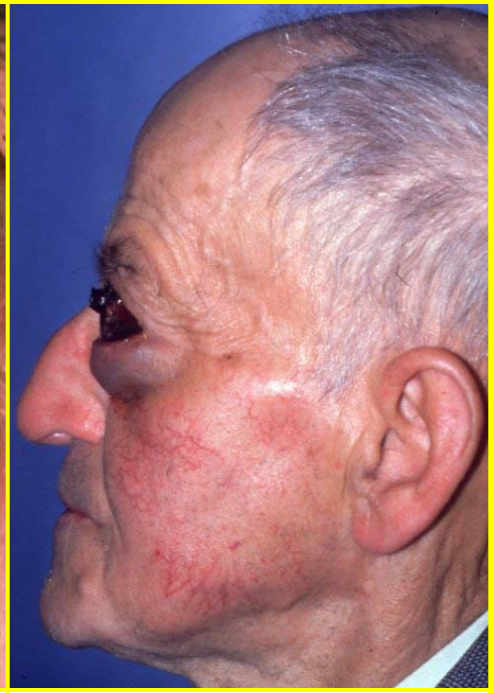
• Excision • Adjunctive cryotherapy	• Excision of nodules • Adjunctive cryotherapy or mitomycin C	• Excision and radiotherapy • Exenteration

Squamous cell carcinoma

Signs	Progression
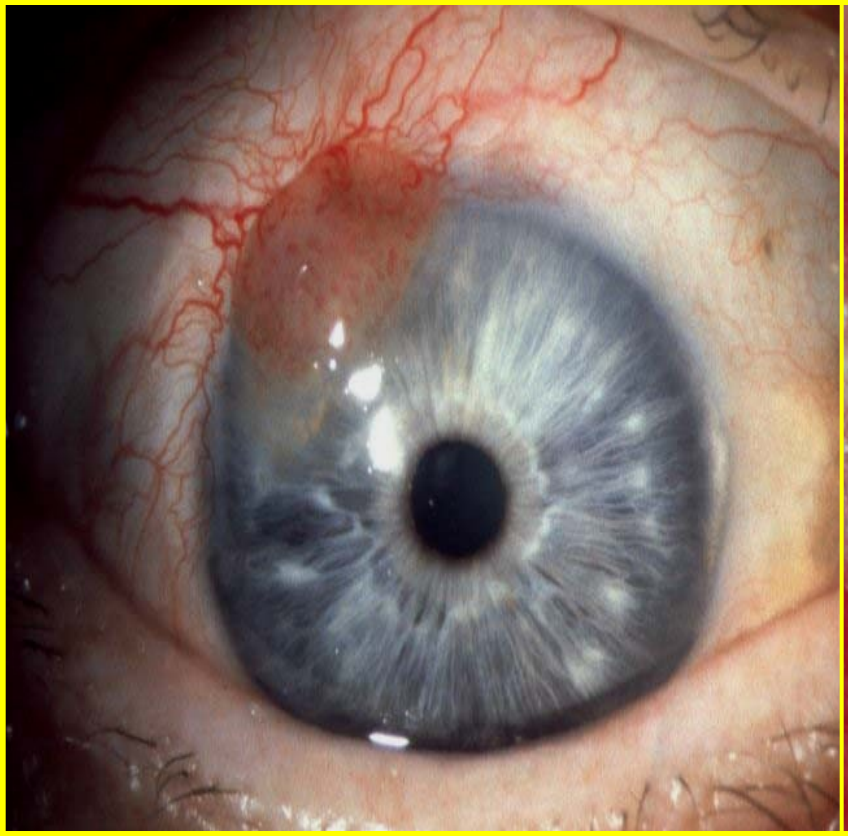	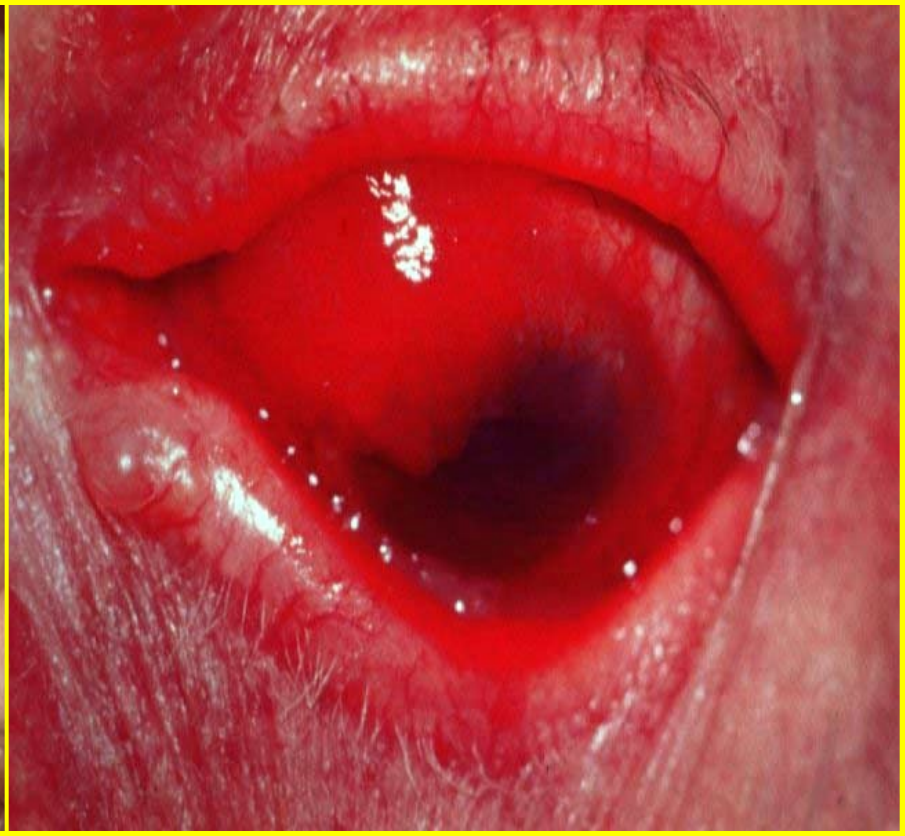
• • Presents in late adulthood • Frequently juxtalimbal	• Slow-growing • May spread extensively • Rarely metastasizes

Kaposi sarcoma

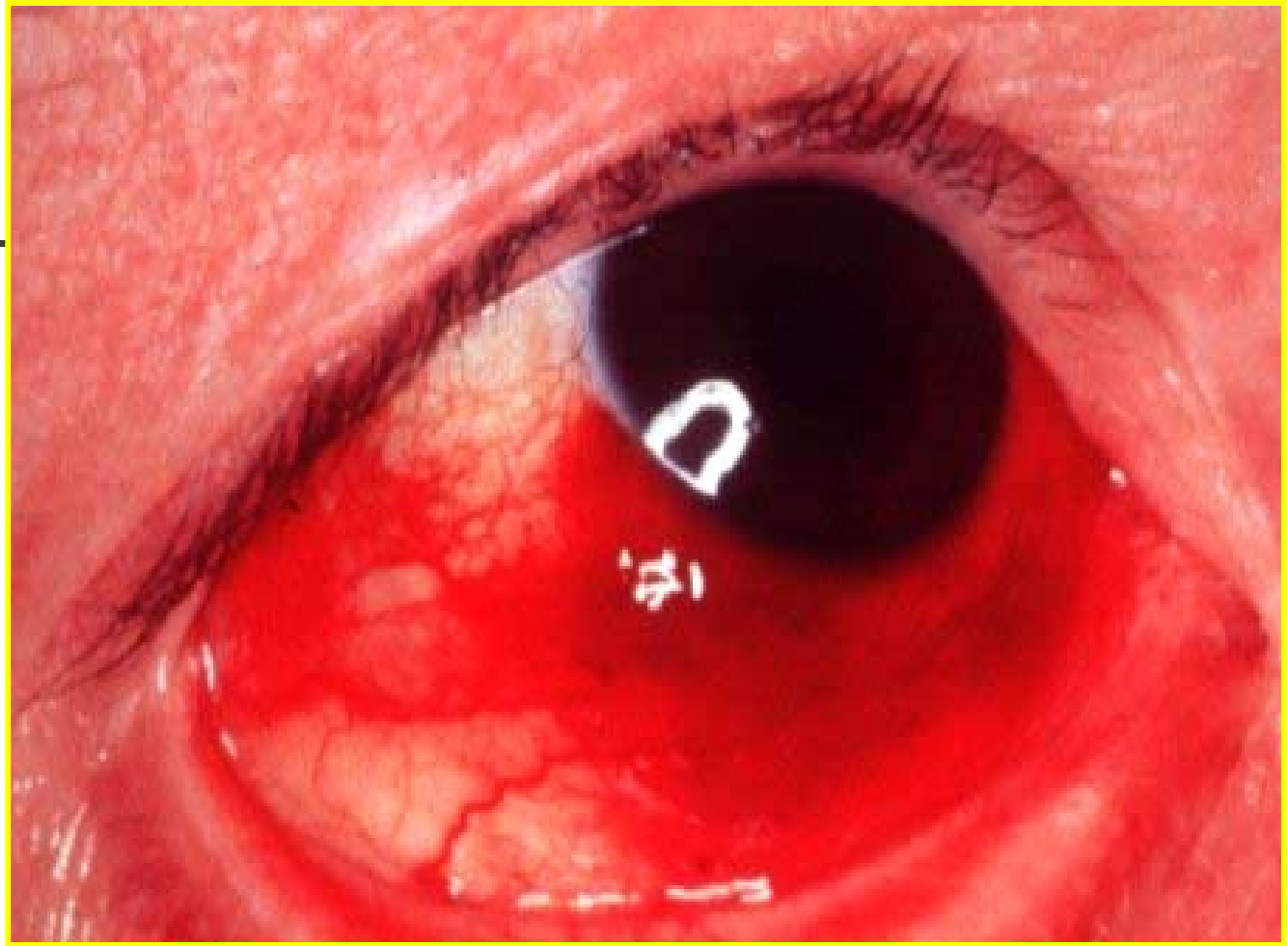

- Affects patients with AIDS
- Vascular, slow-growing tumour of low malignancy
- Very sensitive to radiotherapy
- Most frequently in inferior fornix

Lymphoma

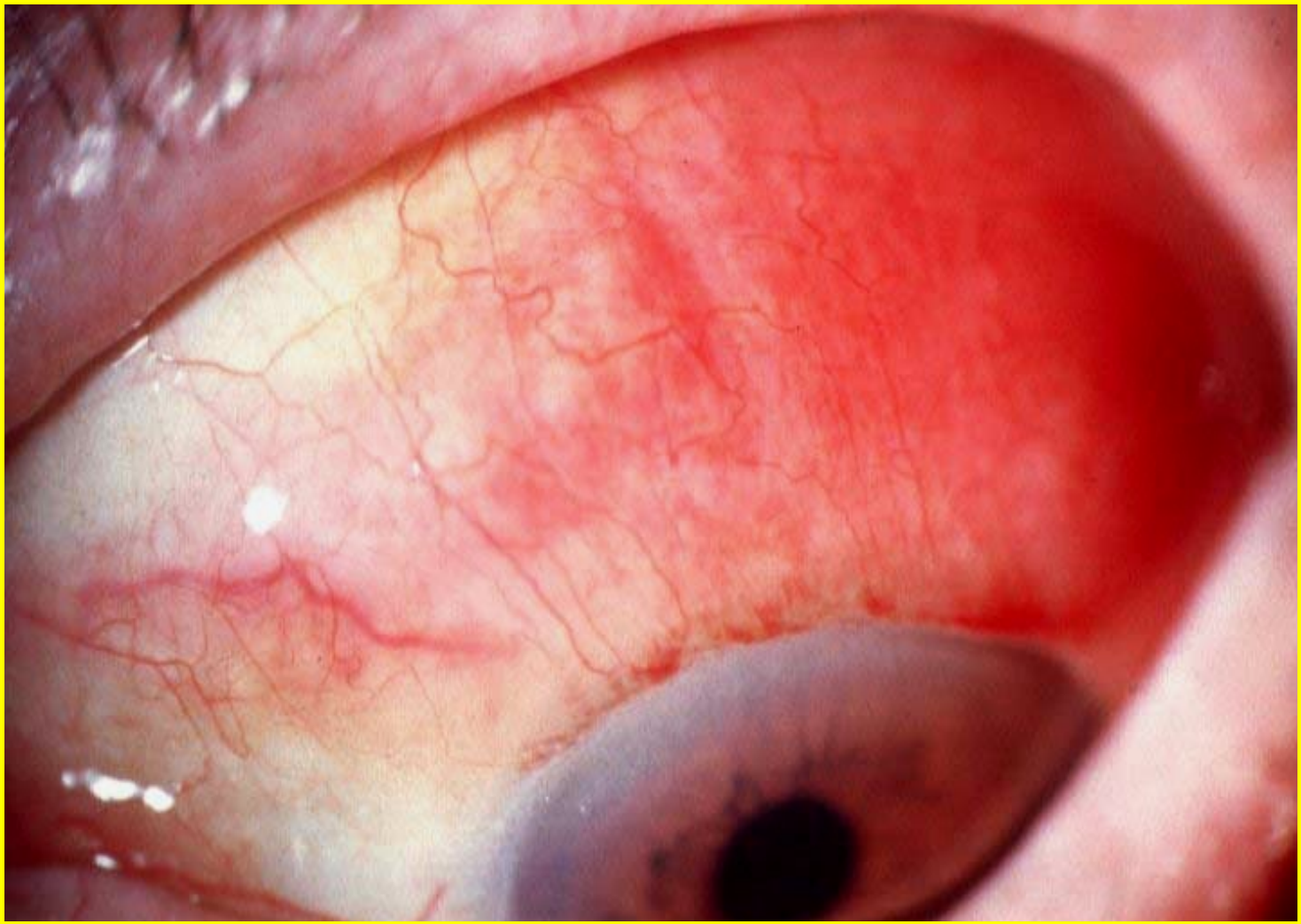

- Usually presents in adulthood
- Benign or malignant
- Salmon-coloured, subconjunctival infiltrate